



# Localized Aggressive Periodontitis in a Six-year-old: A Case Report

Kelly K. Hilgers, DDS   John W. Dean, DDS, PhD   Gregory P. Mathieu, DDS

*Dr. Hilgers is assistant professor, pediatric dentistry, Department of Orthodontics and Pediatric Dentistry, University of Louisville School of Dentistry, Louisville, Ky; Dr. Dean is director of graduate program in periodontology, and Dr. Mathieu is director of graduate program in pediatric dentistry, both at the University of Connecticut School of Dental Medicine, Farmington, Conn.*

*Correspond with Dr. Hilgers at hilgersk@yahoo.com*

## Abstract

The purpose of this report was to describe an approach to diagnose and effectively treat a pediatric patient with localized aggressive periodontitis. A 6-year-old female presented with clinical and radiographic evidence of severe attachment loss around several primary teeth. She had no history of systemic disease, periodontal disease, or caries prior to the periodontal abscess that prompted her referral. Routine immunological tests did not reveal any functional defects, but DNA testing for periodontal pathogens revealed the presence of all 8 aggressive periodontal pathogens assayed. Treatment consisted of the extraction of 2 severely affected primary teeth, increased frequency of recall appointments, and administration of systemic antibiotics. The patient's periodontal condition was stabilized 18 months post-treatment, and the 8 pathogens were no longer at detectable levels. With a treatment goal of preventing disease progression into the erupting permanent dentition, this treatment regimen provides an effective alternative to more aggressive strategies. (*Pediatr Dent.* 2004;26:345-351)

**KEYWORDS:** LOCALIZED AGGRESSIVE PERIODONTITIS, EARLY ONSET PERIODONTITIS

*Received February 11, 2004   Revision Accepted May 5, 2004*

In 1999, a new classification system for periodontal disease was developed at the World Workshop on Periodontics. It includes a greater variety of disease categories, which base the diagnosis on clinical, historical, radiographic, and lab findings rather than the age of onset.<sup>1</sup> One category, aggressive periodontitis, now includes several periodontal conditions that affect those who are otherwise healthy. There tends to be a familial component, and the rate of attachment loss and bone destruction is usually rapid.<sup>1,2</sup> Although bone loss is a rare finding in young children, this disease entity can affect children. In fact, prior to the 1999 revisions, when it occurred in this age group it was previously known by several other names such as "prepubertal periodontitis"<sup>3</sup> and "early onset periodontitis (EOP)".<sup>1</sup> In 1999, Armitage created a comprehensive review of the revisions.<sup>1</sup>

The periodontal disease can be either localized or generalized in aggressive periodontitis cases. The localized form typically has a circumpubertal onset. *Actinobacillus actinomycetemcomitans* and neutrophil function abnormalities are common findings,<sup>2</sup> as are robust serum antibody responses to the pathogens.<sup>1,2</sup> By definition, the localized

form has interproximal attachment loss on at least 2 permanent teeth (one being a permanent first molar), with 2 or fewer permanent teeth other than the first molars or incisors involved.<sup>1</sup> The generalized form usually affects people under 30 years of age, although patients can be older. The attachment loss and bone destruction are typically episodic, affecting at least 3 permanent teeth other than the first molars and incisors,<sup>1</sup> and the disease is frequently associated with *A actinomycetemcomitans*, *Porphyromonas gingivalis*, and neutrophil function abnormalities. The antibody response to the infecting agents is frequently poor.<sup>2</sup>

Secondary features are often, but not always, present in aggressive periodontitis. First, the amount of plaque (ie, microbial deposits) is not necessarily proportional to the disease severity. There may be elevated levels of *A actinomycetemcomitans* and sometimes *P gingivalis*,<sup>1,2</sup> although Lamell found that these pathogens can be transiently found in children of any age without signs of periodontal disease.<sup>4</sup> Second, phagocyte abnormalities may exist, as well as hyper-responsive macrophage phenotypes that include elevated levels of PGE<sub>2</sub> and IL-1B. Finally, the

progression of attachment loss and bone loss may self arrest.<sup>1,2</sup>

Treatment methods for aggressive periodontitis are often similar to those used in chronic periodontitis. These include:

1. oral hygiene instructions;
2. reinforcement and evaluation of the patient's plaque control;
3. supragingival and subgingival scaling and root planing;
4. control of other local factors;
5. occlusal therapy, if necessary;
6. periodontal surgery, if necessary;
7. periodontal maintenance.<sup>2</sup>

Aggressive periodontitis may, however, require additional treatments beyond those of chronic periodontitis. A general medical evaluation may rule out underlying systemic diseases. Adjunctive antimicrobial therapy, as well as microbial identification and antibiotic testing, should be considered.<sup>5</sup> The long-term outcome may depend on patient compliance. When the primary teeth are affected, the eruption of the permanent teeth and their attachment levels should be monitored. Finally, evaluation and counseling of family members is wise, as the disease can be familial.<sup>2</sup>

This report's aim was to follow a systemically healthy child diagnosed with localized aggressive periodontitis for 1 1/2 years after treatment completion. Clinical, radiographic, and lab findings, as well as the patient's response to treatment, are discussed.

### Case description and treatment

In January 2002, a 6-year, 2-month-old healthy white female patient, referred by a periodontist, presented to the University of Connecticut Department of Pediatric Dentistry for the evaluation of possible "localized juvenile periodontitis." The chief complaint was that her parents had been told she had "bone loss around her baby teeth." Her medical history appeared noncontributory, as she was taking no medications, had no known drug allergies, and had no history of any episodic illness. Her mother reported that she had a life-threatening *Escherichia coli* infection in June 1999 (2 1/2 years prior), which resulted in a week of hospitalization. She was treated with the experimental medication Synsorb Pk (Synsorb Biotech Inc, Calgary Alberta Canada). Unfortunately, the infection resulted in hemolytic uremic syndrome and pancreatitis, although both resolved without complication.

The patient had received regular dental care since the age of 2 and had no history of decay or periodontal disease prior to this bone loss episode. The first signs of bone loss began while the patient was vacationing in July 2001. She sought care for a periodontal abscess on tooth I (primary maxillary left first molar) from an oral surgeon, was given Augmentin (GlaxoSmithKline, Research Triangle Park, NC) for 1 week, and returned for extraction of the tooth. During a follow-up examination 1 month later, normal

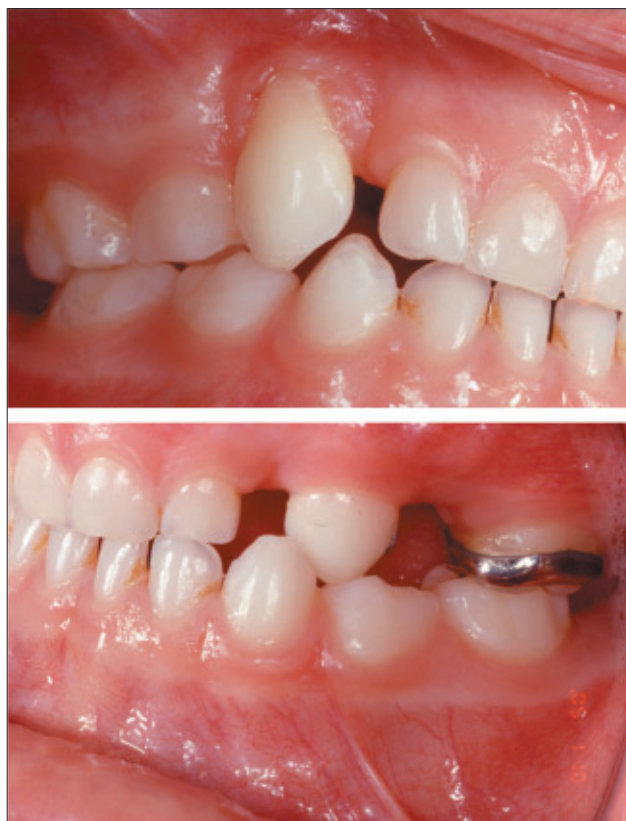

Figure 1. Clinical photographs taken on January 9, 2002, of the patient's right and left sides in occlusion at age 6 years, 2 months.

healing was reported, but tooth C (primary maxillary right canine) had become mobile. The patient was referred to a periodontist, who placed her on chlorhexidine rinse for 30 days and referred her to the University of Connecticut for evaluation.

In October 2001, the patient's pediatrician had evaluated her maxillofacial region with a CT exam, after the patient had suffered from a repeated sinus infection. The pediatrician reported that the patient's paranasal sinuses were clear and there was no evidence of osseous destruction in her maxilla or paranasal sinuses. The pediatrician did not suspect that the *E coli* infection was correlated to the dentoalveolar bone loss.

The clinical oral examination revealed a full primary dentition, with the exception of tooth I (which had been extracted in August 2001). Minimal inflammation of the gingiva was noted, and there was no gingival bleeding. Oral hygiene was excellent, although enamel staining existed due to chlorhexidine use. Probing depths were difficult to obtain due to behavior, but were measured at 7 to 8 mm around teeth C and H (primary maxillary left canines, Figure 1). In addition, severe gingival recession was evident on the buccal of tooth C where the tissue had a rough, granular appearance and lacked stippling (isolated finding). Tooth C also had second-degree mobility based on the modified Miller index of horizontal tooth mobility.<sup>6</sup> Teeth H and M (primary mandibular left canine) were both in crossbite due

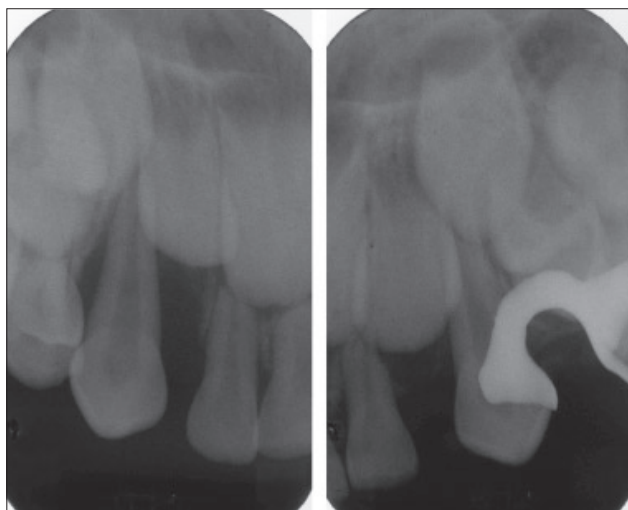


Figure 2. Periapical radiographs taken on January 9, 2002, of teeth C and H at age 6 years, 2 months.

to the space loss after the extraction of tooth I. There was a cast space maintainer present with tooth J (primary maxillary left second molar) banded. Although tooth H had minimal mobility, it was likely stabilized by the space maintainer's arm. No other probing depths exceeded 2 mm, nor were any other teeth excessively mobile. No caries was clinically detectable.

A radiographic examination consisting of anterior and posterior periapical (Figure 2) and bite-wing films revealed severe bone loss around both primary maxillary canines. The remaining teeth appeared unaffected, and the permanent dentition was developing within normal limits. No caries were detected radiographically.

With respect to the patient's family history, her mother and father denied any history of periodontal disease, although they both admitted to previously having "root planing" performed. The patient's 10-year-old brother received regular dental care and never prematurely exfoliated primary teeth nor had any history of decay or bone loss. Upon examination, the patient's brother showed no evidence of decay nor any abnormality in his exfoliation and eruption patterns. His oral hygiene was excellent, and periodontium appeared healthy. All probing depths were less than 2 mm, and there was no evidence of any excessive mobility. Bite-wing radiographs presented no evidence of alveolar bone loss.

Based on the patient's age, severity of bone loss in isolated areas, and lack of systemic disease, a preliminary diagnosis of localized aggressive periodonti-

tis was made.<sup>1</sup> The Department of Periodontology at the University of Connecticut was consulted, as was the patient's pediatrician, who ordered a complete blood count (CBC) with differential and fasting blood glucose level to rule out systemic disease.

The treatment plan consisted of a fairly conservative approach, due to the lack of generalized disease, in which only affected teeth were extracted. Her parents understood that progression of the disease to a more generalized form might necessitate the extraction of more (or all) primary teeth. The primary goal was to prevent bacterial spread to the erupting permanent dentition. Bacteriologic samples were planned to identify periodontal pathogens in the affected sites, and a tissue biopsy would be taken of the abnormal tissue on the facial side of tooth C. The patient was to receive antibiotic therapy for 10 days after treatment.<sup>5</sup> Follow-up appointments would be frequent, and if no disease progression occurred, the patient would be offered the option of fabricating "pedi-partials" to temporarily replace teeth C, H, and I and to maintain space.

Since aggressive periodontitis has been correlated to infections with certain highly aggressive pathogens, such as *A actinomycetemcomitans* and *P gingivalis*,<sup>2</sup> DNA testing (MicroDenteX DMDx Test, Fort Myers, Fla) for periodontal pathogens was performed using the subgingival crevicular fluid of the mesiofacial pockets of both teeth C and H. The extraction of teeth C and H, removal of the space maintainer, and biopsy of the gingival tissue on the facial side of tooth C were also performed. The biopsied tissue and extracted teeth were then submitted for pathological analysis.

The patient began Augmentin therapy for 10 days (40 mg/kg/day divided into 3 doses), although it was explained that the antibiotic might be changed, depending on the lab results. Chlorhexidine therapy (0.5-oz rinse twice a day)

Table 1. DNA Test Results

| DNA test results                            |                                |                   |                   |                                       |
|---|--------------------------------|-------------------|-------------------|---------------------------------------|
|   | 1/31/02                        | 1/20/03           | 6/12/03           |                                       |
| Tested pathogen                             | Pooled tooth C (MF) and H (MF) | Tooth no. 19 (DB) | Tooth no. 24 (DF) | Pooled teeth nos. 19 (MB) and 24 (DF) |
| <i>Actinobacillus actinomycetemcomitans</i> | Moderate                       | High              | Negative          | Negative                              |
| <i>Prevotella intermedia</i>                | High                           | Negative          | Low               | Negative                              |
| <i>Porphyromonas gingivalis</i>             | Negative                       | Low               | Negative          | Negative                              |
| <i>Eikenella corrodens</i>                  | Negative                       | Negative          | Moderate          | Negative                              |
| <i>Campylobacter rectus</i>                 | Negative                       | Low               | Negative          | Negative                              |
| <i>Bacteroides forsythus</i>                | Negative                       | Negative          | Moderate          | Negative                              |
| <i>Treponema denticola</i>                  | Negative                       | Moderate          | Low               | Negative                              |
| <i>Fusobacterium nucleatum</i>              | Negative                       | Negative          | Moderate          | Negative                              |

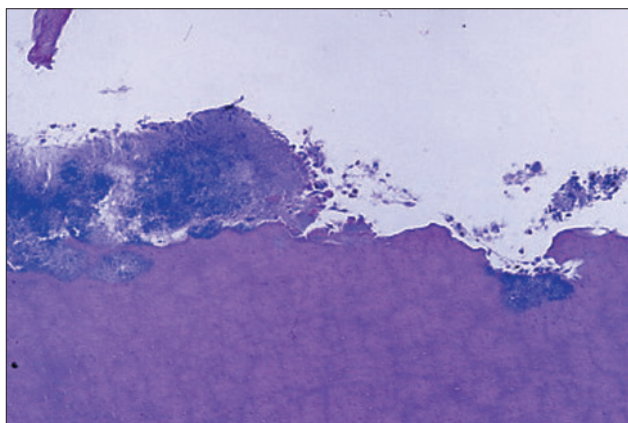


Figure 3. Photomicrograph of the root surface of the primary maxillary right canine (tooth C), demonstrating an irregular external resorption pattern with abundant colonies of microorganisms, at magnification of  $\times 250$ , and with hematoxylin and eosin (H&E) stain.

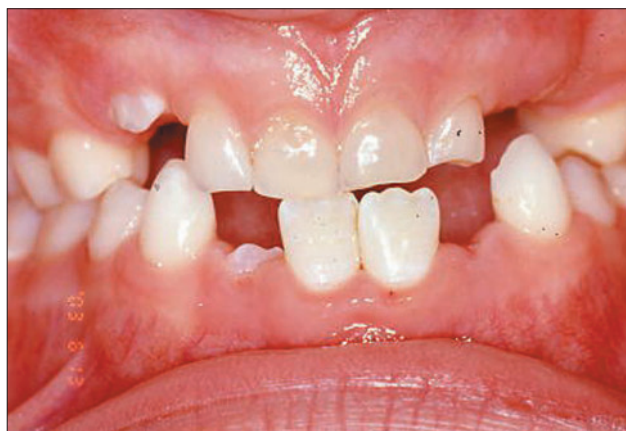

Figure 4. Clinical photograph taken on June 12, 2003, of the patient's anterior occlusion at age 7 years, 8 months.

was resumed, and the patient was scheduled for a 1-month follow-up appointment.

### Hematologic and bacteriological/pathological results

The patient's CBC with differential lab results were within normal limits, except for a slight elevation of lymphocytes and light decrease in polymorphic nucleocytes (PMNs). Fasting blood glucose levels were also within normal limits.

The DNA test results are reported semiquantitatively as "negative" (corresponding with  $<10^3$  organisms), "low" ( $10^3$  to  $10^4$  organisms), "moderate" ( $10^4$  to  $10^5$  organisms), and "high" ( $>10^5$  organisms). As listed in Table 1, the results reported moderate levels of *A actinomycetemcomitans*, high levels of *Prevotella intermedia*, and negative levels of *P gingivalis*, *Eikenella corrodens*, *Campylobacter rectus*, *Bacteroides forsythus*, *Treponema denticola*, and *Fusobacterium nucleatum*.

The biopsy results depicted the gingival margin of tooth C to be chronic granulation tissue (inflammatory fibrous hyperplasia). The root cementum of teeth C and H was also noted to be very thin (Figure 3), with an irregular external resorptive pattern and abundant colonies of microorganisms. To rule out hypophosphatasia, serum phosphoethanolamine levels were requested (which were later reported as normal). After evaluation of all test results, the diagnosis of localized aggressive periodontitis was confirmed.

The patient was seen for follow-up at 6 weeks, 3 months, 6 months, and 9 months. At each visit, she received a thorough exam, prophylaxis, and appropriate radiographs. No changes in her periodontal condition were noted. Pedipartials were discussed, but the patient showed a complete lack of interest. Due to her lack of interest, rapidly changing transitional dentition, and the appliance's potential to harbor bacteria, they were not fabricated. Crowding issues would be addressed in the future; space loss was already present. The patient continued with chlorhexidine rinses until 2 weeks prior to the 12-month follow-up, to allow microbial DNA testing to be performed.

During the 12-month follow-up examination, all tissues appeared healthy and without inflammation. Teeth nos. 14, 19, and 30 had almost completely erupted, while teeth nos. 3, 24, and 25 were partially erupted. All probing depths were less than 2 mm, and a full-mouth radiographic survey revealed no additional bone loss. No caries was evident clinically or radiographically. No abnormal mobility was noted. The parents were concerned about the permanent dentition's inadequate spacing. It was recommended that the parents consult an orthodontist upon the completed eruption of all incisors and permanent first molars.

The follow-up DNA testing for periodontal pathogens using subgingival crevicular fluid is listed in Table 1. Test results of the distal operculum of tooth no. 19 reported low levels of *P gingivalis* and *C rectus*, moderate levels of *T denticola*, and high levels of *A actinomycetemcomitans*. *P intermedia*, *E corrodens*, *B forsythus*, and *F nucleatum* were at negative levels. Test results of the distofacial of tooth no. 24 reported that *P intermedia* and *T denticola* levels were low and *E corrodens*, *B forsythus*, and *F nucleatum* were moderate. *A actinomycetemcomitans*, *P gingivalis*, and *C rectus* were negative. Because the aggressive anaerobic pathogens were not eliminated after the use of Augmentin, metronidazole therapy was indicated.<sup>5,7,8</sup>

After consultation with her pediatrician, the patient began taking 250 mg of metronidazole 3 times a day for 14 days and resumed rinsing with 0.5 oz chlorhexidine twice a day for 30 days. Her mother also began more diligently flossing the patient's teeth daily. The patient returned for prophylaxis during the systemic drug therapy.

The patient was seen for a 15-month follow-up appointment. Oral hygiene was excellent and no gingival inflammation was present. All probing depths were  $<2$  mm and without bleeding. The patient was scheduled for follow-up DNA testing in 3 months, and oral hygiene was reinforced. Chlorhexidine rinses were reinstituted again until 3 weeks prior to the follow-up appointment.

During the 18-month follow-up examination, all tissues again appeared healthy (Figure 4). Teeth nos. 3, 14, 19,

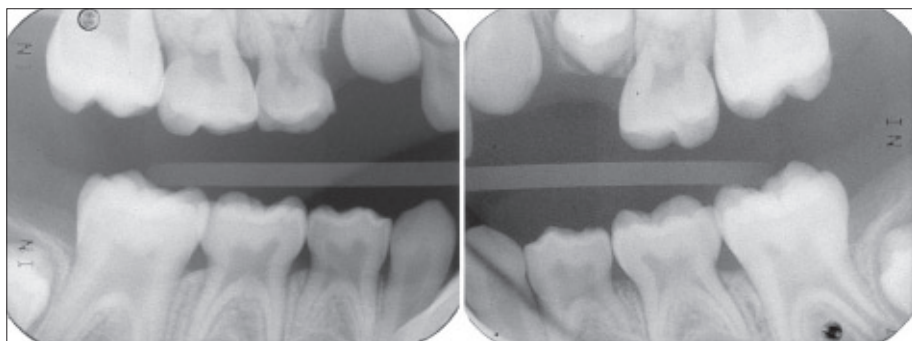


Figure 5. Bite-wing radiographs taken on June 12, 2003, of the patient's right and left side at age 7 years, 8 months.

24, 25, and 30 were completely erupted. Teeth D, E, F, and G (primary maxillary incisors) had normal mobility for the patient's dental development stage. All probings were less than 2 mm, and bite-wing radiographs revealed no bone loss (Figure 5). No caries was evident clinically or radiographically, and oral hygiene was excellent.

Follow-up DNA testing for aggressive periodontal pathogens detected none of the 8 tested for in either of the sites (mesiobuccal of tooth no. 19 nor distofacial of tooth no. 24; Table 1). The patient received an oral prophylaxis and was reappointed for regular follow-up in 3 months.

## Discussion

In this report, the authors describe a treatment approach for early-onset localized aggressive periodontitis. The most striking feature of this patient's condition was the severity of bone loss in isolated areas relative to her age. Localized aggressive periodontitis usually has a circumpubertal onset, with periodontal damage being localized to the permanent first molars and incisors.<sup>2</sup> Due to this patient's age and growth stage, only her primary teeth were affected at presentation. In the past, some practitioners have very aggressively treated young patients with similar, often more generalized forms of aggressive periodontitis. Because some practitioners believe the disease to be a precursor to periodontitis in the permanent dentition,<sup>9</sup> extracting all primary teeth to prevent the sharing of aggressive periodontal pathogens with newly erupted/erupting permanent teeth has been advocated.<sup>10</sup>

As described by Bodur,<sup>11</sup> 3 of the main characteristics of localized aggressive periodontitis in a child were observed: (1) mobility and loss of teeth; (2) presence of putative periodontal pathogens; (3) lack of cementum. The patient presented in this study was a 6-year-old female who lost a maxillary first molar due to a periodontal abscess and, later, lost her primary maxillary canines due to advanced bone loss. No other destruction in the periodontal apparatus of her remaining teeth was evident at 1 1/2 years post-treatment. Consequently, permanent mandibular incisors and first permanent molars erupted, seemingly unaffected by the previous periodontal infections.

In contrast to generalized aggressive periodontitis, localized aggressive periodontitis usually occurs in patients who are otherwise healthy.<sup>2</sup> This child was systemically healthy, except for a previous *E coli* infection at the age of 4 (in June 1999, 2 1/2 years prior to the onset of symptomatic dental problems). Although the patient's physician felt that the previous infection had completely resolved and was not a factor in the later development of peri-

odontal disease, it is unclear whether the *E coli* infection could have played a role; it was not evaluated in the microbiologic profile. No correlation has been made between systemic *E coli* infections and periodontal disease in the medical literature.

Consistent with other reports of localized aggressive periodontitis, initial DNA microbial testing indicated the presence of the periodontal pathogens *A actinomycetemcomitans* and *P intermedia*, but no neutrophil function abnormality was detected (as can be common in such cases).<sup>2,12</sup> In 1987, Wojcicki<sup>13</sup> reported that populations of *P intermedia* are typically very low in prepubescent children and much higher in circumpubertal and postpubertal children. In contrast, it has been suggested more recently that localized periodontitis presenting in children is not only associated with *A actinomycetemcomitans* but is likely the result of polyinfections by a mixture of bacteria (especially *P gingivalis* and *P intermedia*) similar to adult or chronic disease.<sup>14</sup> Other species likely to be involved include; *Capnocytophaga* species, *E corrodens*, *C rectus*, spirochetes, and *Eubacterium* species.<sup>14,15</sup> Other current reports, however, have stated that *P gingivalis* and *T denticola* were not detected in periodontally healthy children, but several putative periodontal pathogens can colonize early in childhood.<sup>16</sup>

Although the patient appeared clinically to be asymptomatic, 12-month follow-up microbial DNA testing was used to determine whether the erupting permanent dentition was infected with aggressive periodontal pathogens. Unfortunately, *A actinomycetemcomitans*, *P intermedia*, *P gingivalis*, *T denticola*, *E corrodens*, *B forsythus*, *F nucleatum*, and *C rectus* were all detected, suggesting that the microbial flora was still characteristic of that found in periodontitis. For therapy to be considered successful, the levels of aggressive pathogens such as *A actinomycetemcomitans* needed to be significantly reduced or eliminated from the flora.<sup>14</sup> Therefore, childhood colonization with periopathogens without active disease warranted the use of additional, more specific antibiotic therapy (metronidazole).

Adjunctive systemic antibiotic use with mechanical debridement is an acceptable treatment option for *A actinomycetemcomitans*-associated periodontal disease.<sup>5</sup> Currently, however, no specific antibiotic is considered the

standard, and many options exist.<sup>5,7,8</sup> The antibiotic initially chosen post-extraction was Augmentin. This selection was made because it is resistant to a wide range of beta-lactamases, which are produced by many oral bacteria, and because it is a broad-spectrum antibiotic with good oral absorption. Because the 12-month follow-up microbial DNA test demonstrated the continued presence of aggressive anaerobic periodontal pathogens after completing a regimen of Augmentin, the use of metronidazole was deemed necessary.<sup>5,7,8</sup> Although this drug is rarely used in children for dental infection (it is more commonly used for trichomoniasis and amebiasis), the aggressive nature of her periodontal disease and presence of newly erupting permanent teeth warranted its use.

As recommended by the patient's pediatrician and the Department of Periodontology at the University of Connecticut, the dosing schedule was 30 mg/kg per day divided into 3 doses for 14 days. This was determined from the normal dosing regimen for children with amebiasis, which is 35 to 50 mg/kg per day for 7 to 10 days.<sup>17</sup> Common side effects of metronidazole therapy include: (1) nausea; (2) vomiting; (3) headache; (4) seizure; (5) rash; (6) fever; and (7) peripheral neuropathy. The patient did report vomiting one time on the last day of her metronidazole therapy. No other side effects were reported.

Another promising option is the combined therapy of metronidazole and amoxicillin.<sup>5</sup> When taken concurrently, amoxicillin has been shown to increase the bacterial cell uptake of metronidazole.<sup>7,8</sup> Tetracycline was not used because of the reported resistance of oral bacteria to tetracycline and possible adverse effects it has on developing crowns.<sup>5</sup>

The University of Connecticut Department of Periodontology recommended a final DNA microbial test a minimum of 60-90 days after the completion of antibiotic therapy and 21 days after the completion of antimicrobial rinses to ensure the detection of new colonies of periodontal pathogens. Such tests did not reveal the presence of any of the pathogens.

Previously, Page and Baab<sup>18</sup> suggested that in "prepubertal periodontitis" patients a major determinant of disease progression may be the abnormal deposition of root cementum. They hypothesized that the thin cementum could result in abnormal attachment, thus making affected teeth highly susceptible to periodontal pathogen invasion. Another association between early presentation of periodontal disease and thin cementum has been described in patients with hypophosphatasia.<sup>19</sup> This systemic disorder, however, was ruled out after her serum alkaline phosphatase levels were found to be normal.

The present case report's results indicated 2 viable alternatives to other more aggressive approaches:

1. extraction of hopelessly involved teeth;
2. short-term use of systemic antibiotics in localized aggressive periodontitis in a young healthy child prior to the eruption of the permanent dentition.

Although microbial testing found *A actinomycetemcomitans* and *P intermedia* prior to the treatment initiation, and later, the presence of additional aggressive periodontal pathogens, the disease appeared to have been controlled and the periodontal pathogens decreased to undetectable levels after 18 months of follow-up.

## Acknowledgements

The authors would like to acknowledge Dr. Ellen Eisenberg for her insightful contributions to this case report and assistance with the pathologic analyses.

## References

1. Armitage G. Development of a classification system for periodontal diseases and conditions. *Ann Periodontol*. 1999;4:1-6,53.
2. American Academy of Periodontology. Parameter on aggressive periodontitis. *J Periodontol*. 2000;71:867-869.
3. Page R, Bowen T, Altman L, et al. Prepubertal periodontitis. I. Definition of a clinical disease entity. *J Periodontol*. 1983;54:257-271.
4. Lamell CW, Griffen AL, McClellan DL, Leys EJ. Acquisition and colonization stability of *A actinomycetemcomitans* and *P gingivalis* in children. *J Clin Microbiol*. 2000;38:1196-1199.
5. Walker C, Karpinia K. Rationale of use of antibiotics in periodontics. *J Periodontol*. 2002;73:1188-1196.
6. Laster L, Laudendach KW, Stoller NH. An evaluation of clinical tooth mobility measurements. *J Periodontol*. 1975;46:603-607.
7. Pavicic MJ, vanWinkelhoff AJ, Pavicic-Temming YA, deGraaff J. Amoxycillin causes an enhanced uptake of metronidazole in *Actinobacillus actinomycetemcomitans*: A mechanism of synergy. *J Antimicrob Chemother*. 1994;34:1047-1050.
8. Pavicic MJ, vanWinkelhoff AJ, Douque NH, Steures RW, deGraaff J. Microbial and clinical effects of metronidazole and amoxicillin in *Actinobacillus actinomycetemcomitans*-associated periodontitis. A 2-year evaluation. *J Clin Periodontol*. 1994;21:107-112.
9. Sjodin B, Matsson L, Unell L, Egelberg J. Marginal bone loss in the primary dentition of patients with juvenile periodontitis. *J Clin Periodontol*. 1993;20:32-36.
10. Tinanoff N, Tanzer JM, Kornman KS, Maderazo EG. Treatment of the periodontal component of Papillon-Lefevre Syndrome: A case report. *J Clin Periodontol*. 1986;13:6-10.
11. Bodur A, Bodur H, Balos K. Generalized aggressive periodontitis in a prepubertal patient: A case report. *Quintessence Int*. 2001;32:303-308.
12. Crossner CG, Carlsson J, Sjodin B, Tarnvik A, Unell L, Venge P, Wranne L. Periodontitis in the primary dentition associated with *Actinobacillus actinomycetemcomitans* infection and leukocyte dysfunction. A 3 1/2 year follow-up. *J Clin Periodontol*. 1990;17:264-267.

13. Wojcicki CJ, Harper DS, Robinson PJ. Differences in periodontal disease-associated microorganisms of subgingival plaque in prepubertal, pubertal, and post-pubertal children. *J Periodontol.* 1987;58:219-223.
14. Darby I, Curtis M. Microbiology of periodontal disease in children and young adults. *Periodontol 2000.* 2001;26:33-53.
15. Suda R, Lai C, Yang H, Hasegawa K. Eikenella corrodens in subgingival plaque: Relationship to age and periodontal condition. *J Periodontol.* 2002;73:886-891.
16. Kimura S, Takashi O, Takiguchi M, Sasaki Y, Amano A, Morisaki I, Hamada S. Periodontopathic bacterial infection in children. *J Periodontol.* 2002;73:20-26.
17. Antibacterial Drugs. In: Beers MH, Berkow R, eds. *The Merck Manual.* 17th ed. Whitehouse Station, NJ: Merck Research Laboratories; 1999:1118.
18. Page RC, Baab DA. A new look at the etiology and pathogenesis of early onset periodontitis. Cementopathia revisited. *J Periodontol.* 1985;56:748-751.
19. Oh T, Eber R, Wang H. Periodontal Diseases in the Child and Adolescent. *J Clin Periodontol.* 2002;29:400-410.

## ABSTRACT OF THE SCIENTIFIC LITERATURE



### DEGLUTITION AND MAXILLOFACIAL MORPHOLOGY

Deglutition is a basic and important physiological function. Subjects with anterior open bite may display a deviated swallowing pattern. This clinical study evaluated the relationship between deglutition and maxillofacial morphology in 10 female subjects with anterior open bite and compared them to 10 control subjects without anterior open bite. Statistically significant correlations ( $P < .05$ ) were observed between mandibular plane angle, ramus height, anterioposterior dimension of the maxilla, or gonial angle and characteristic tongue movement during 3 stages of deglutition in subjects with anterior open bite.

**Comments:** Oral and facial musculature played a significant role in craniofacial growth and development. Although the sample size was small and the results might not apply to other gender or ethnic groups, this study was well designed and demonstrated the influence of abnormal tongue movement and swallowing pattern on craniofacial features. **BL**

*Address correspondence to Dr. Teruko Takano-Yamamoto, Department of Orthodontics and Dentofacial Orthopedics, Okayama University Graduate School of Medicine and Dentistry, 2-5-1 Shikata-Cho, Okayama City, Okayama 700-8525, Japan.*

Fujiki T, Inoue M, Miyawaki S, Nagasaki T, Tanimoto K, Takano-Yamamoto T. Relationship between maxillofacial morphology and deglutitive tongue movement in patients with anterior open bite. *Am J Orthod Dentofacial Orthop.* 2004;125:160-167.

21 references