The Pendulis Appliance for Bone-Anchored Maxillary Molar Distalization

- FRANÇOIS-JOSEPH NAPPÉE DDS, MS
- MAGALI NAPPÉE-MIÉVILLY DDS
- JAMES J. HILGERS DDS, MS

The original Pendulum[*] appliance[1] and its subsequent modifications and improvements[2-6] are efficient devices for treating Class II malocclusions while minimizing the need for compliance. Since the early 2000s, several bone-anchored distalizers based on TMA[**] springs have been developed to combine the efficacy of Hilgers's original Pendulum with miniscrew anchorage.[7-12] Using temporary anchorage devices (TADs) appears to be the best way to avoid the anchorage loss that occurs with toothborne appliances and still allow spontaneous distal drift of the posterior teeth. What has been lacking in these boneborne appliances is the opportunity for the clinician to remove the entire device so that adjustments and reactivation can be performed outside the mouth.

This article describes a new bone-anchored Pendulum that uses a single TAD and can easily be removed for midcourse adjustments (Fig. 1). We call this evolution the Pendulis,[***] a portmanteau of "Pendulum" and "minivis" (the French word for miniscrew).[13-14]

Fabrication

The innovative part of the Pendulis is a stainless steel Unitek O-Cap[†] that can be snapped on and off the head of a palatally placed 3M miniscrew[‡] (Fig. 2). Once the cap is

seated on the screw, its retention and stability are reliable enough to support a Pendulum-like distalizer comprising a Nance acrylic button and two .032" TMA springs, which fit into lingual molar sheaths. The traditional Pendulum is attached to the anchorage unit by means of a short .040" stainless steel arm, with one end soldered to the O-Cap and the other embedded in the acrylic Nance button.

SIMILAR ARTICLES FROM THE ARCHIVE:

- Hybrid Hyrax Distalizer and Mentoplate for Rapid Palatal Expansion, Class III Treatment, and Upper Molar DistalizationCLARENBACH, WILMES, IHSSEN, VASUDAVAN, DRESCHERJune 2017
- Rapid Maxillary Expansion and Upper-Molar Distalization with a Miniscrew-Supported Hybrid ApplianceHOURFAR, RUFF, WILMES, LUDWIG, KANAVAKISAugust 2016
- OVERVIEW Upper-Molar Distalization and the Distal JetBOWMANMarch 2016

Fig. 1 Pendulis*** appliance.

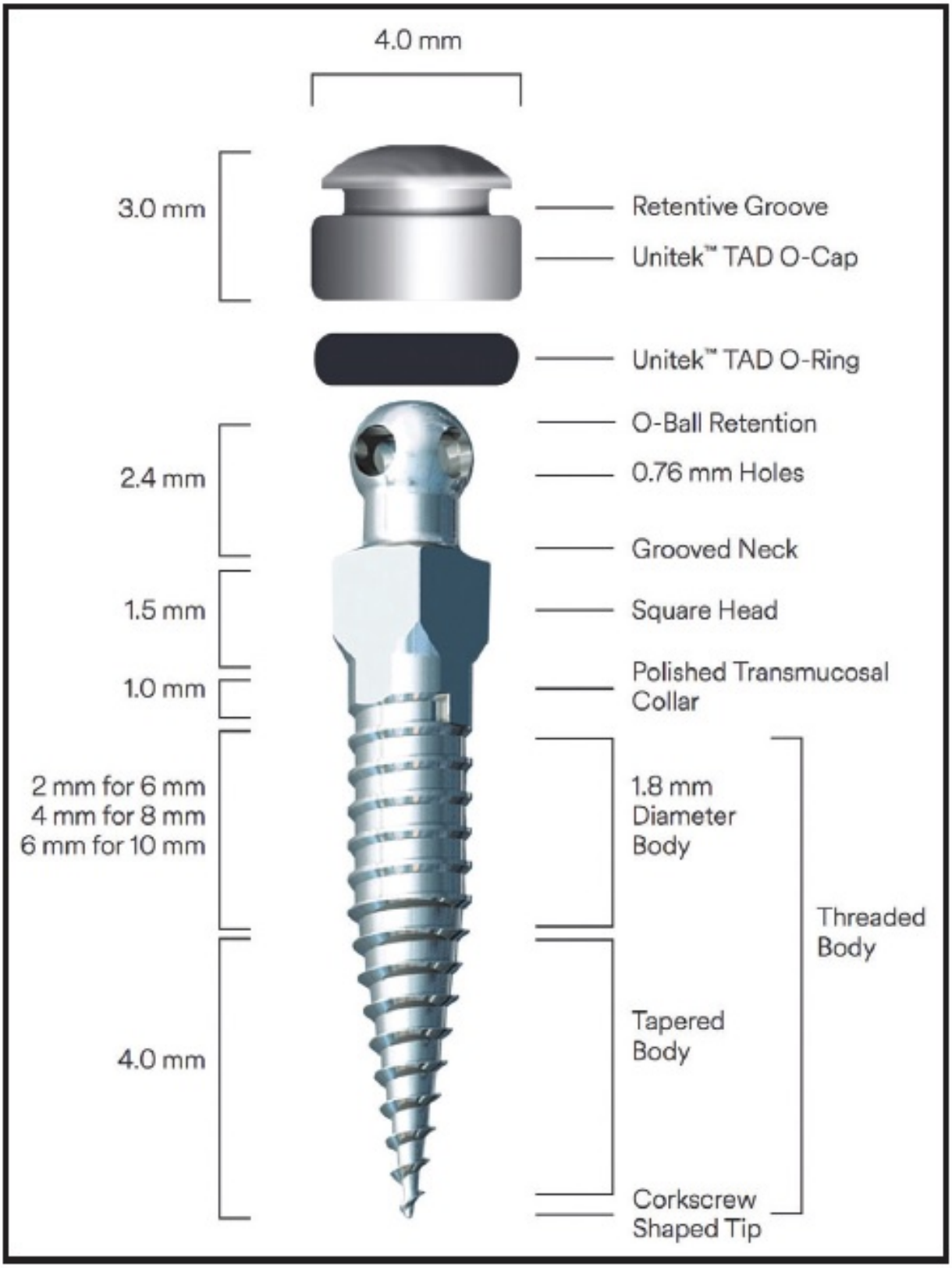

Fig. 2 3M Unitek miniscrew‡ with rubber O-Ring† and weldable O-Cap.† (Illustration courtesy of 3M, St. Paul, MN.)

After delivery of local or topical anesthesia, a 3M miniscrew 8mm or 10mm in length (depending on the mucosal and bone thickness) is placed in the anterior palate using a contra-angle manual or motorized screwdriver. Although an implant can be safely placed in either the median or paramedian area,[15] we prefer a paramedian insertion on the left side of the anterior palate for right-handed doctors (conversely for left-handers). This contralateral placement enables comfortable manipulation of the anterior TAD attachment arm with a Weingart plier. The TAD should be placed as anteriorly as possible to allow sufficient space for the other Pendulis components.[16] The angle of insertion should be approximately perpendicular to the palate at the site of insertion. The emerging head must be totally clear of the palate to make sure the O-Cap will fit over the screw without touching the mucosa, thus facilitating hygiene control around the appliance.

Before taking an alginate impression with the miniscrew in place, use a fingertip to cover the emerging screw head with impression material. Alternatively, take a three-dimensional digital impression and then 3D-print a plastic or resin model (Fig. 3). Handle the thin, 3D-printed screw head carefully to avoid breakage. After the impression procedure, place a temporary O-Cap over the screw head for patient comfort until appliance delivery.

The technician will insert a transfer analog in the hole created in the impression material by the emerging head to enable replication of the screw's exact position in the palate (Fig. 4). A small drop of quick-set epoxy glue can be

added to the head of the analog before placement to secure it during shipment to the laboratory.

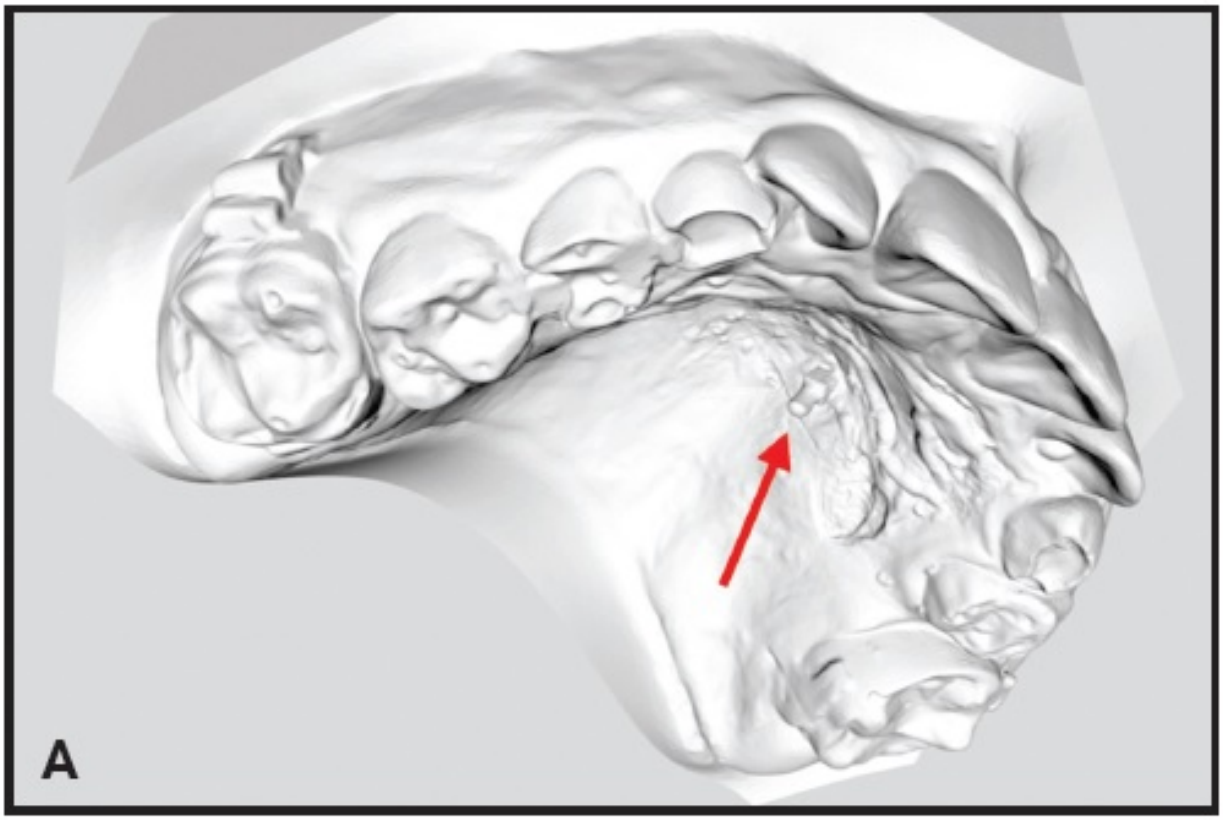
A

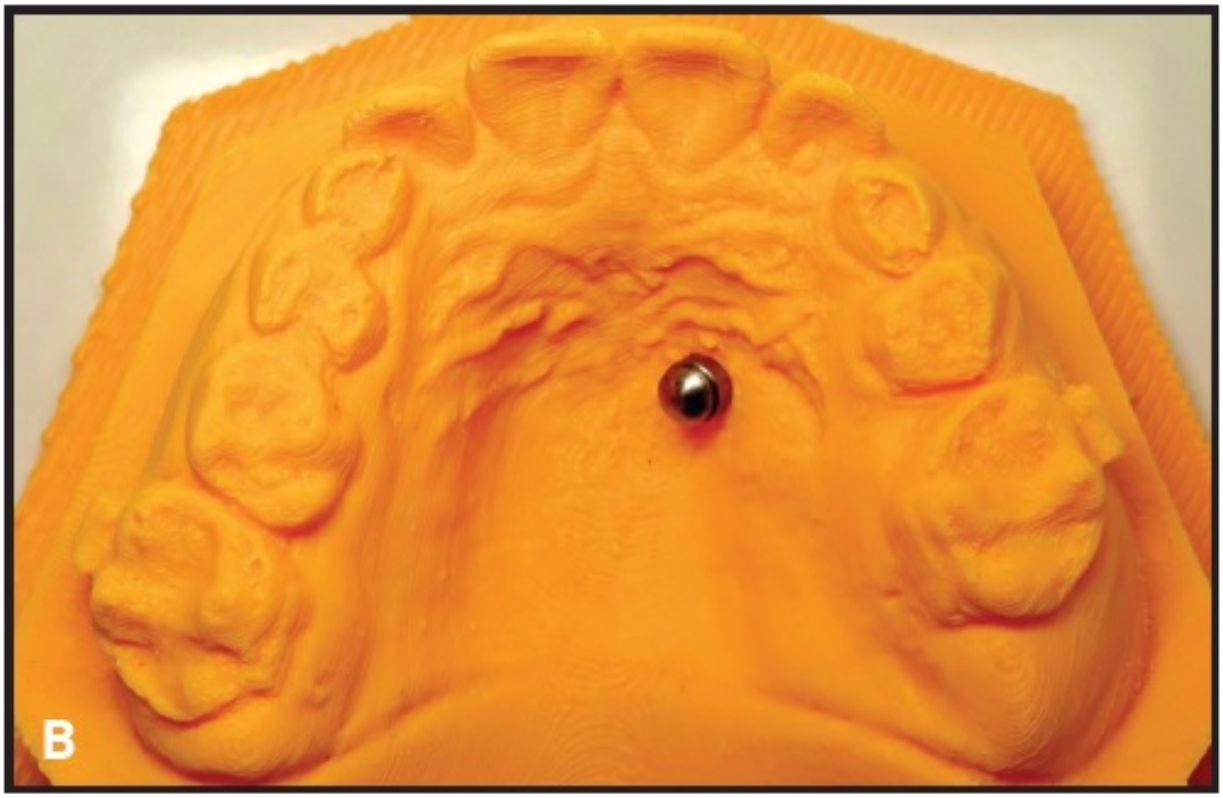
B

Fig. 3 A. Red arrow on three-dimensional digital impression indicates emerging miniscrew head, which must be precisely recorded. B. Plastic 3D-printed model illustrates perfect fit of O-Cap on printed screw head.

Fig. 4 A. Transfer analog with head similar to that of miniscrew. B. Retentive portion of analog submerged in impression before shipping to laboratory, with head covered by quick-set epoxy glue for retention. C. Finished cast.

The inner O-Ring[‡] joint must be temporarily removed before soldering because of the high temperatures involved (Fig. 5A). If the ring is damaged during removal, it can be replaced. Although rarely needed, a new O-Ring can also be inserted at the time of appliance placement. To make the anchorage portion of the appliance, silver- or laser-solder the stainless steel arm to an O-Cap (Fig. 5B). Bend the arm to conform to the cast, so that its retention loop can be embedded in the acrylic Nance button (Fig. 5C).



Fig. 5 A. Plastic O-Ring removed before soldering. B. Stainless steel arm soldered to O-Cap. C. Arm bent to conform to cast, with some wire left free to provide handle for Weingart plier during placement and removal.

Embed two .032" or .036" TMA pendulum springs in the 5mm-thick posterior shelf of a Nance button (Fig. 6). The acrylic must be thick enough to keep the distal portions of the springs safely away from the palate. Although the horizontal adjustment loop of the spring can be either mesially or distally oriented, a distal orientation will avoid distortion of the posterior acrylic during appliance placement. The distal ends of the springs can be recurved to aid in molar tip and torque control during distalization. Traditional burring and polishing procedures complete the fabrication process (Fig. 7). We use clear acrylic, polished as well as possible, to allow observation of any mucosal bleaching, which would indicate excessive pressure from the button on the palate.

Activation and Placement

Every step of Pendulis handling can be safely accomplished with a Weingart plier. Activation is essentially the same as with the original Pendulum appliance, involving backward bending of the pendulum springs (Fig. 8).

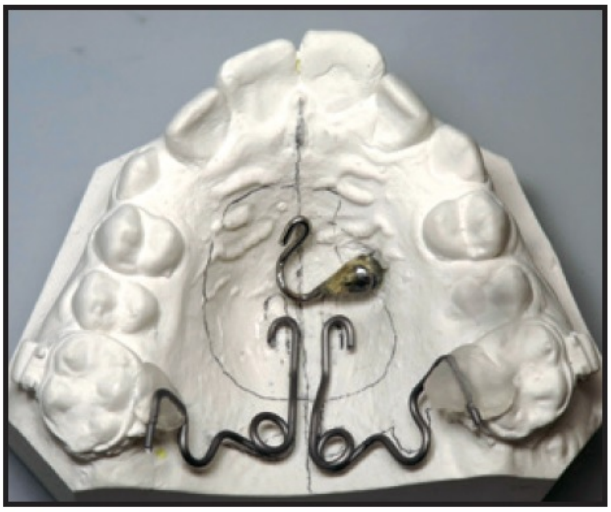

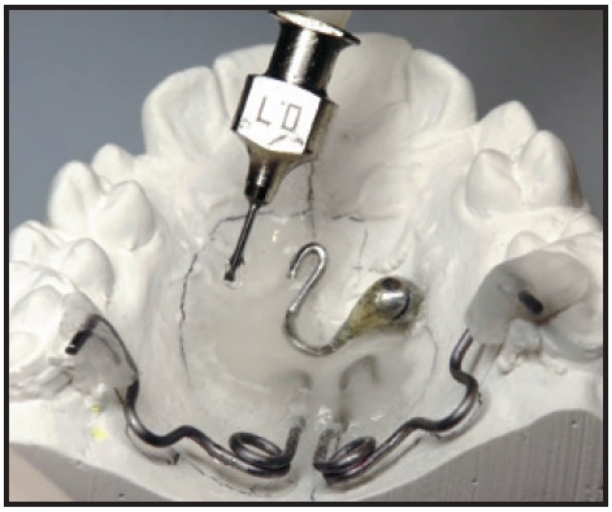

Fig. 6 Two .036" TMA** springs embedded in 5mm-thick posterior shelf of clear acrylic Nance button.

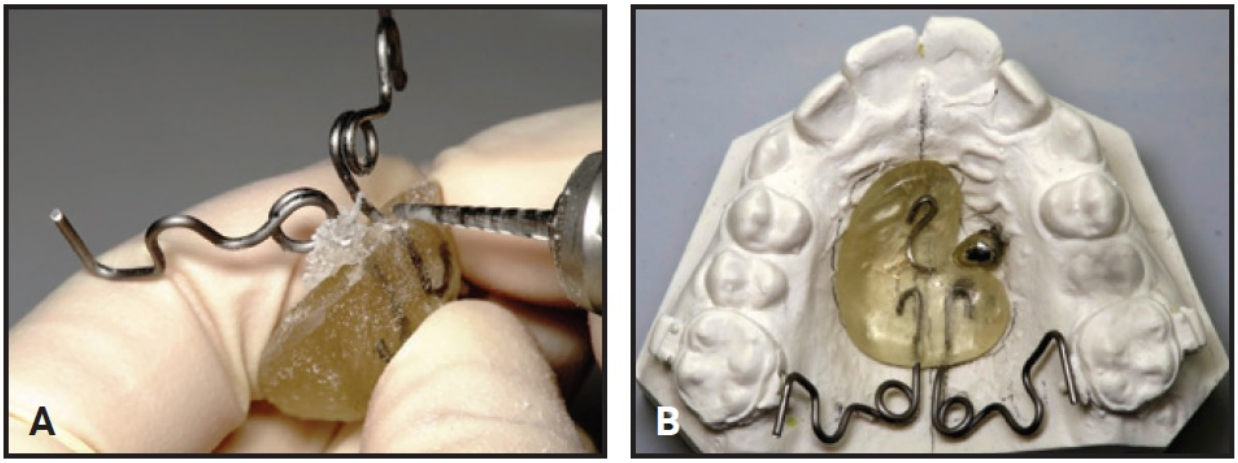

Fig. 7 A. Bur used to smooth edges of Nance button. B. Finished appliance after thorough polishing.

Fig. 8 Activation using Weingart plier and finger pressure on distal part of spring loop, as with traditional Pendulum appliance.

Because the appliance is anchored by a single miniscrew, we recommend adding some expansion to both springs to enhance lateral stability, prevent rotation of the O-Cap around the screw, and counter the natural tendency of Pendulum-like distalizers to cause inward tipping of the molars. Because the Pendulis is easy to insert and remove, it does not have to be fully activated for initial placement, enabling greater precision of subsequent molar distalization, vertical control, and rotation without distal tipping. To avoid excessive pressure on the screw, especially when distalizing both first and second molars, activate one side at a time every four weeks. Once

sufficient distalization has been achieved, the Pendulis can be kept in place with a slight distalizing activation to prevent relapse and to provide efficient anchorage for buccal-segment distalization and incisor retraction as needed.

Placement can begin either by snapping on the O-Cap or inserting the distal ends of the springs into the sheaths, depending on the clinician's preference and patient comfort. Seating the springs first may help avoid unwanted bending or deactivation that can result from the springs moving forward before insertion (Fig. 9).

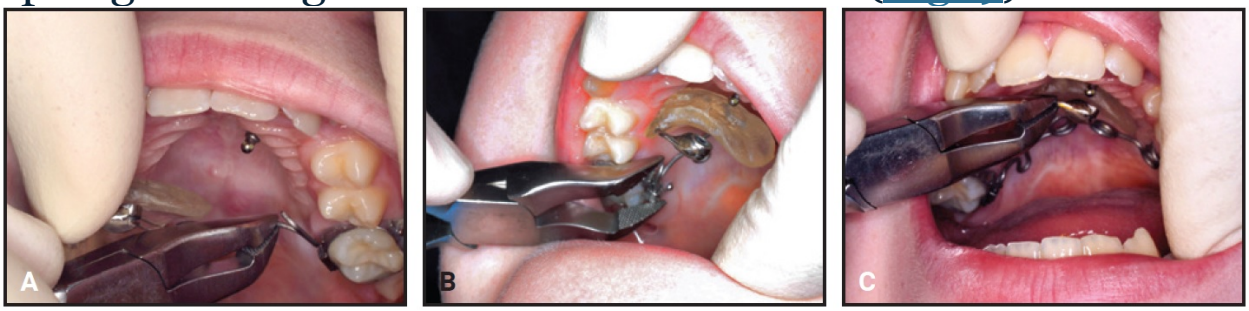

Fig. 9 A. Pendulum springs inserted into palatal sheaths. B. Gingival right-angle bend made at distal end of spring to facilitate seating in sheath. C. Placement completed by clipping O-Cap onto screw head and adjusting for comfort.

Since the difference in torque between the molars and the Pendulis springs can be an important factor at this stage of appliance placement, it may be useful to place gingival right-angle bends at the distal ends to facilitate handling with the pliers. Elastomeric or stainless steel ligatures are not needed because the distal force is permanent.

After placement, check for any discomfort, especially excessive pressure on the palate from the Nance button or the springs. Any required bends can be made inside or outside the mouth.

The original Pendulum appliance and its modifications have sometimes been criticized for promoting poor hygiene during long-term wear of the acrylic button. The

Pendulis appliance should be removed and cleaned at each appointment, and a fresh wet compress should then be applied to the palate. This is also a good time to check the stability of the TAD by gently striking it with a dental mirror handle.

Case 1

A 13-year-old female presented with a Class II malocclusion and midline deviation (Fig. 10, Table 1).

Fig. 10 Case 1. 13-year-old female patient with Class II malocclusion, midline deviation, and labially erupting upper left canine before treatment.

TABLE 1
CASE 1 CEPHALOMETRIC ANALYSIS

	Pretreatment	After Distalization*	Difference
Distal tipping			
SN-U7	67.2°	65.0°	2.2°
SN-U6	71.1°	68.2°	2.9°
SN-U5	73.5°	72.9°	0.6°
Distal movement			
PtV-U7	11.0mm	8.2mm	2.8mm
PtV-U6	20.1mm	17.4mm	2.7mm
PtV-U5	28.2mm	25.1mm	3.1mm
Extrusion			
PP-U7	11.5mm	12.1mm	0.6mm
PP-U6	14.5mm	14.5mm	0.0mm
PP-U5	16.3mm	16.0mm	0.3mm

*Measured after 20 months of treatment; distalization required six months.

The upper left canine was erupting labially. A Pendulis appliance was placed on the upper second molars, and upper and lower .022" MBT± Clarity± and SmartClip± self-ligating brackets were bonded (Fig. 11).

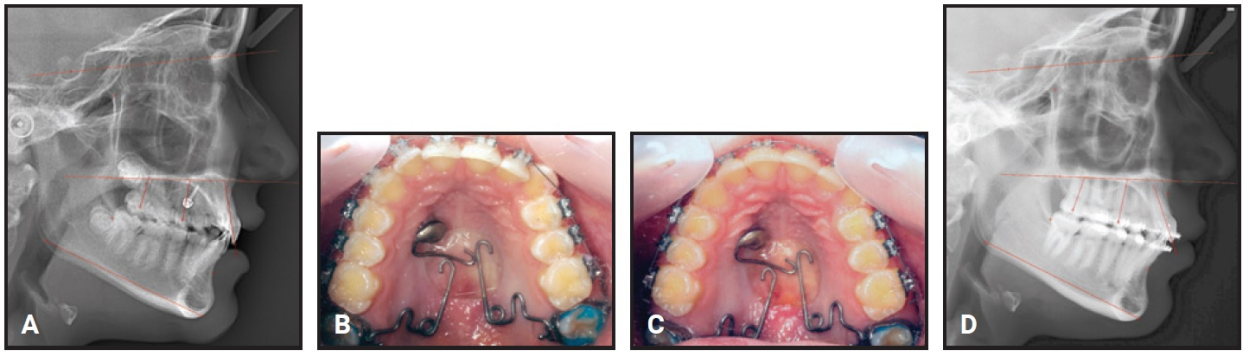

Fig. 11 Case 1. A. Before distalization, with miniscrew in place. B. After two months of distalization with Pendulis appliance. C. After four months. D. After 20 months of treatment, including six months of distalization with Pendulis.

The Pendulis was activated for six months until the upper second molars were successfully distalized, and remained passively in place for another six months to reinforce posterior anchorage. A series of upper and lower .014", .016", .0175" × .0175", and .019" × .025" nickel titanium archwires was used over the course of treatment.
Total treatment time was 24 months (Fig. 12). Comparison of x-rays before and after distalization demonstrated good control of root angulation.[11,17] Effective distal movement of the posterior and buccal segments was observed, with only minor distal tipping and no unwanted extrusion (Table 1).

Fig. 12 Case 1. Patient after 24 months of treatment.

Case 2

A 13-year-old male presented with Class I canine and Class II molar relationships; both upper second premolars were palatally ectopic (Fig. 13).

Fig. 13 Case 2. 13-year-old male patient with Class II molar relationship and palatally ectopic upper second premolars before treatment (radiograph taken two years before treatment).

A Pendulis was placed on the upper first molars (Fig. 14), and upper and lower .022" MBT Clarity and SmartClip self-ligating brackets were bonded. Four months after placement of the Pendulis appliance, the molars were in a Class I relationship (Fig. 15).

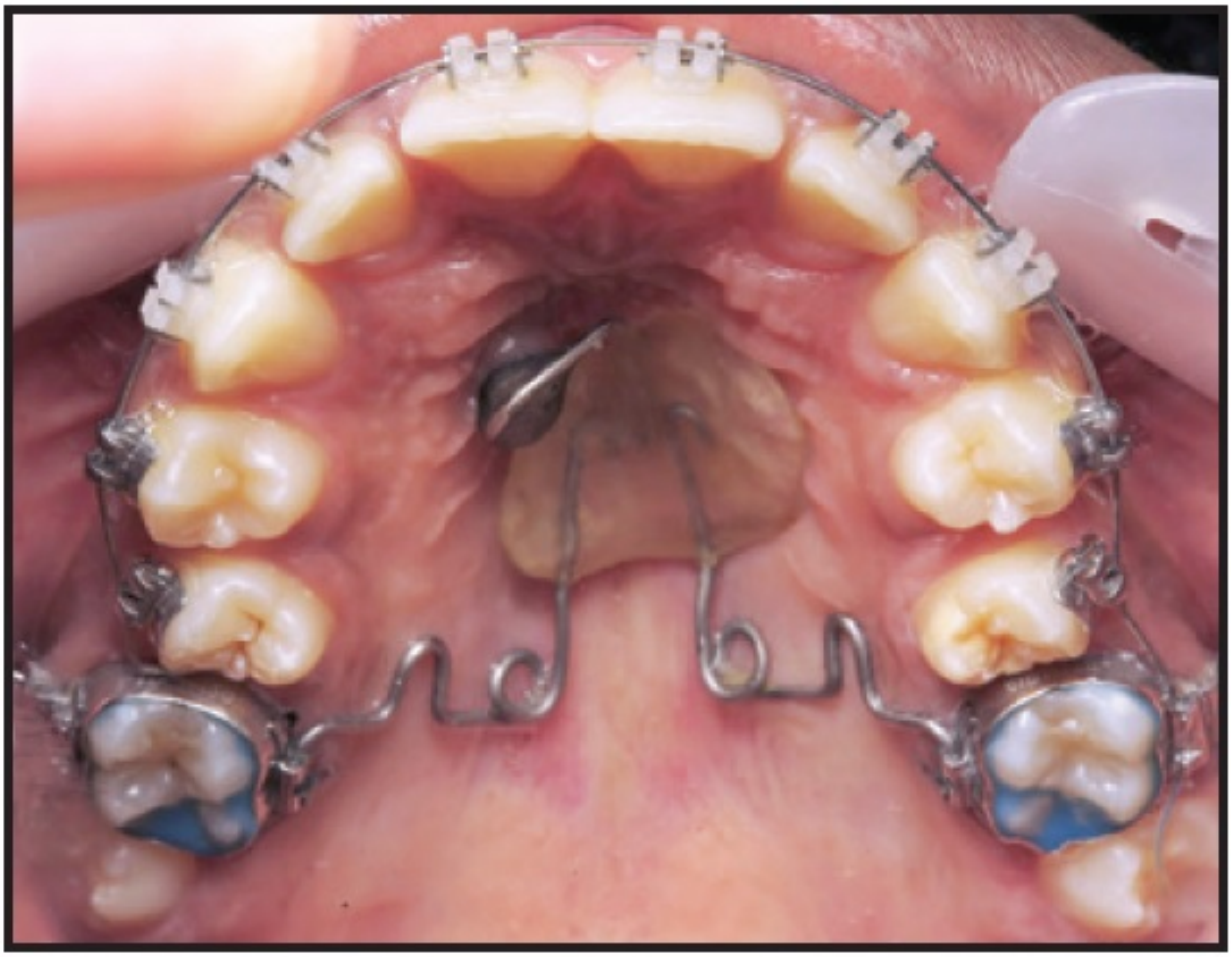

Fig. 14 Case 2. After two months of distalization with Pendulis.

Fig. 15 Case 2. Class I molar relationship achieved after four months of distalization.

The activation period lasted eight months (owing to several missed appointments), and the Pendulis was then left passively in place for another nine months for posterior anchorage reinforcement (Fig. 16).

Because of the patient's deep bite, we bonded bite turbos to the upper central incisors after distalization and kept them in place for six months. In the upper arch, the archwire sequence was .012", .016", .0175" × .0175", and

.019" × .025" nickel titanium; .017" × .025" TMA with bull loops and added anterior torque; and .019" × .025" nickel titanium. In the lower arch, a series of .012", .014", .016", .0175" × .0175", and .019" × .025" nickel titanium archwires was used.

Total treatment time was 28 months (Fig. 17). The panoramic x-ray sequence showed appropriate distal movement of the posterior and buccal segments.

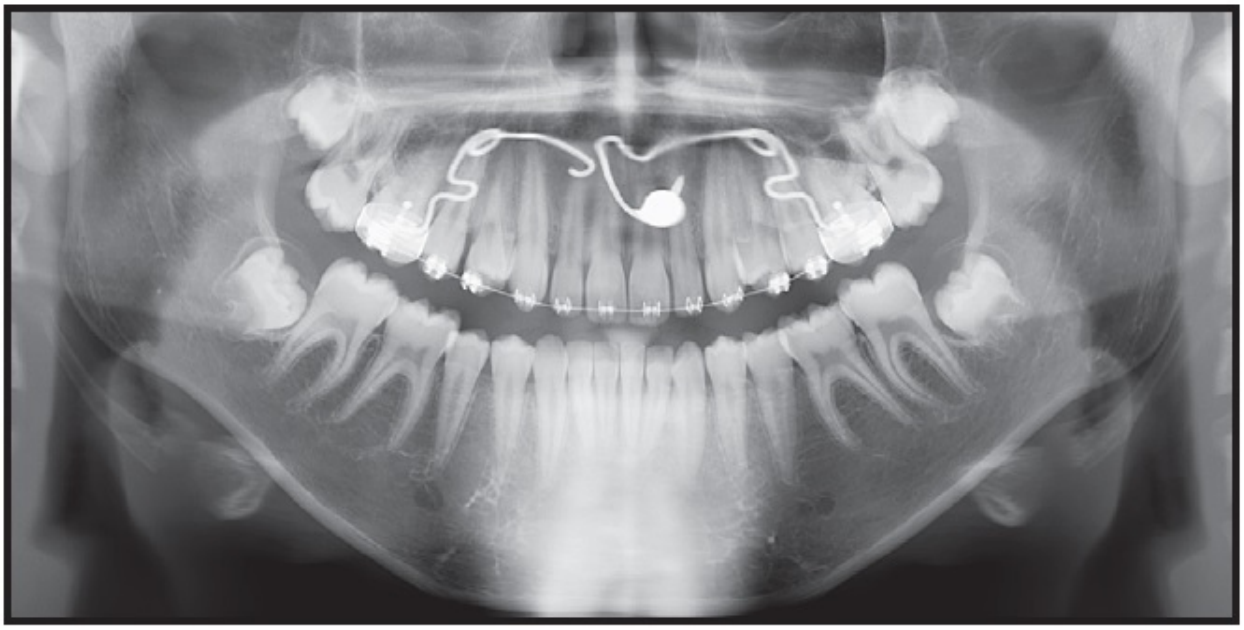

Fig. 16 Case 2. After 15 months of treatment, including eight months of distalization with Pendulis.

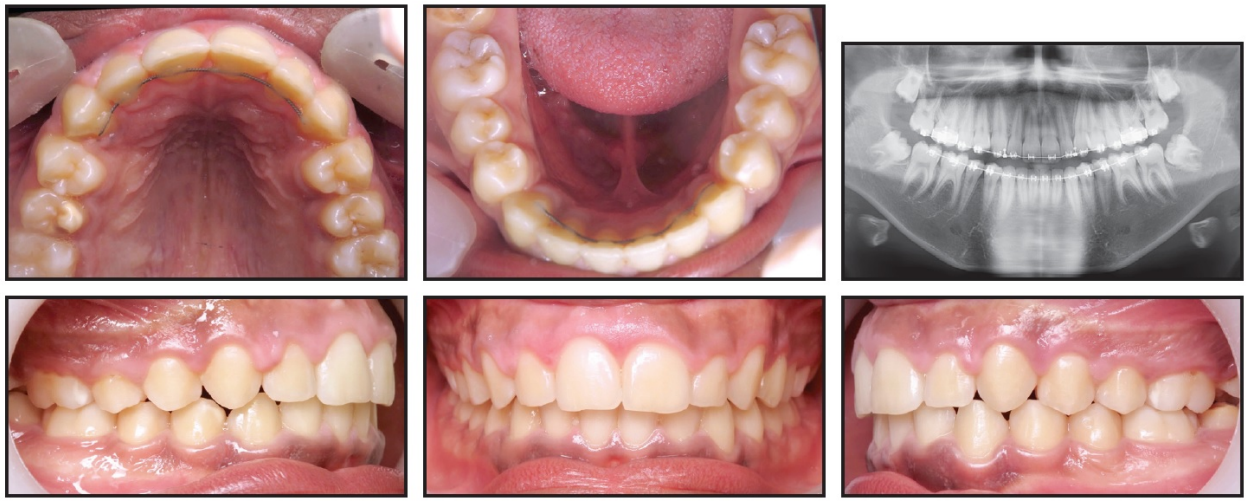

Fig. 17 Case 2. Patient after 28 months of treatment (radiograph taken before debonding).

Discussion

The Pendulum and its toothborne modifications addressed a need for a simple Class II non-compliance device, but it was not without issues. The more recent boneborne evolutions of the appliance resolved the problem of anchorage loss while maintaining dental support (especially important in children) and allowing spontaneous distal drift of the premolars. Unfortunately, most of these devices also had the disadvantages of higher cost and technical or clinical complexity.

The Pendulis reestablishes the original appliance's simplicity and reliability. It can be used without anchorage loss and left in place if needed for secondary posterior anchorage. Its removability improves precision and hygiene, and the use of a single palatal miniscrew will reassure practitioners who may be reluctant to prescribe TAD-supported appliances.

The Pendulis is highly efficient in a variety of clinical situations (Fig. 18).

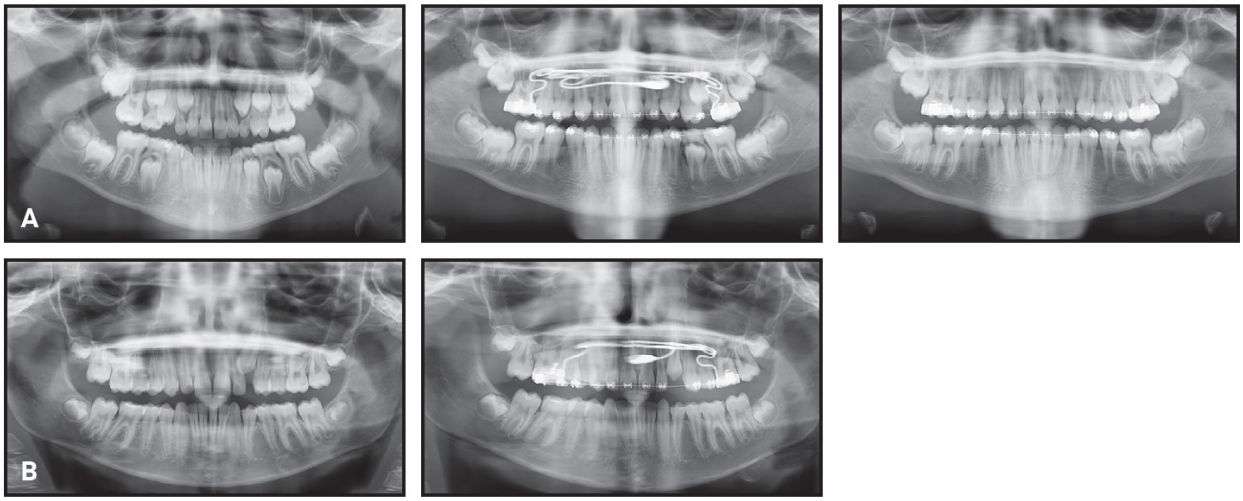

Fig. 18 Additional applications of Pendulis appliance. A. Spontaneous eruption of impacted upper premolars after molar distalization. B. Spontaneous distal drift and uprighting of palatally impacted upper left canine during distalization.

The elasticity of the pendulum springs allows concomitant correction of molar rotation and, unlike sliding-based distalizers, enables some expansion to be performed during distal movement. For patients with palatally impacted canines, the appliance can be constructed with a more distal miniscrew by switching the positions of the O-Cap and acrylic button (Fig. 19A). While an 8mm or 10mm TAD usually provides sufficient monocortical anchorage, bicortical anchorage may be needed in patients with thin palates; in such a case, an anchorage auxiliary can be embedded in the button (Fig. 19B).

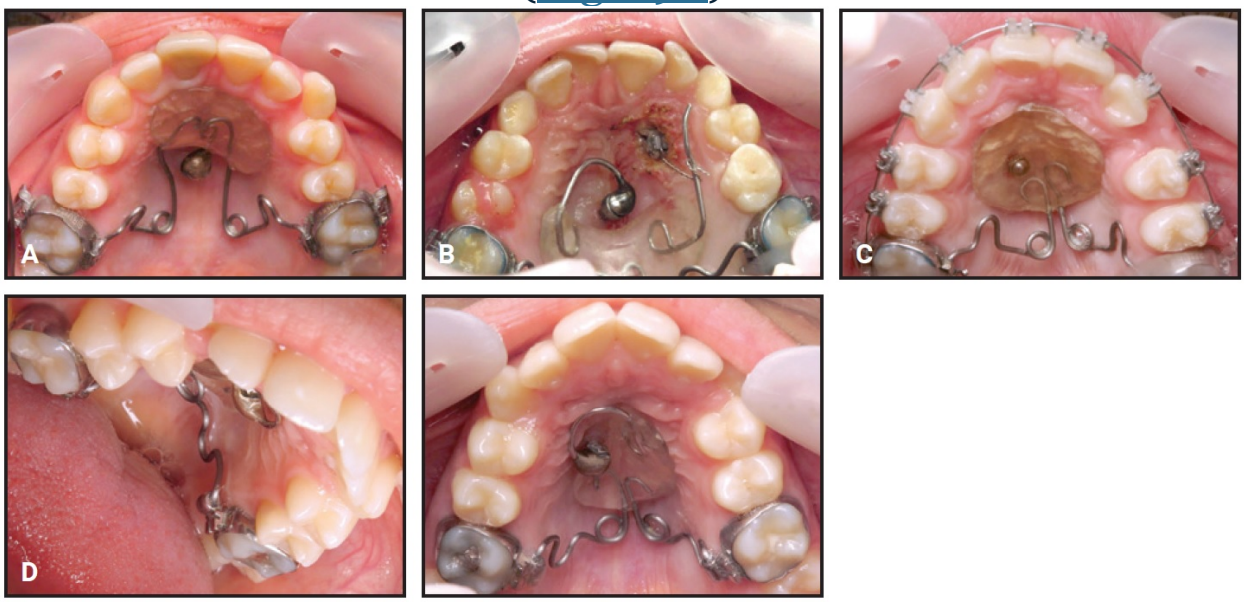

Fig. 19 Pendulis variants. A. Inverted mounting of acrylic button and O-Cap. B. Embedded auxiliary for additional anchorage. C. Embedded O-Cap. D. Pendulis attached to first molar bands for lingual treatment.

An additional stainless steel arm provides useful anchorage for movement of an impacted tooth during molar distalization. The O-Cap can also be embedded, although this version is more awkward to work with because there is no easy-access handle to grip with the plier (Fig. 19C).

If the upper second molars are present—especially in an adult patient—a stronger distalizing force can be applied to the upper first molars by using .036" TMA springs. To use the traditional .032" springs, the upper second molars should be banded before distalizing the first molars, as in Case 1. This approach can be helpful in cases of severe first molar and second premolar crowding. The Pendulis can also be used in lingual treatment, but the palatal sheaths will be positioned more palatally and apically, which may result in less tipping and more undesirable rotation. This can be avoided by adding toe-in bends to the sheath ends of the springs (Fig. 19D).

No cone-beam computed tomography is needed in most cases, because the miniscrew is placed in a low-risk insertion site. The analog transfer technique is easily performed by any lab technician, and the possibility of using 3D models and printing makes the Pendulis a digital-friendly system. In summary, the Pendulis can be a useful distalizing tool in everyday practice, with little chairtime needed for placement, reactivation, and removal.

FOOTNOTES

- *Ormco Corporation, Orange, CA; www.ormco.com.
- **Trademark of Ormco Corporation, Orange, CA; www.ormco.com.
- ***Pendulis Orthodontics, Cergy, France; www.pendulisorthodontics.com.
- †Trademark of 3M, Monrovia, CA; www.3M.com.
- ‡3M, Monrovia, CA; www.3M.com.

COMMENTS

REFERENCES

- 1. Hilgers, J.J.: The Pendulum appliance for Class II non-compliance therapy, J. Clin. Orthod. 26:706-714, 1992.

- 2. Kinzinger, G.S.; Eren, M.; and Diedrich, P.R.: Treatment effects of intraoral appliances with conventional anchorage designs for non-compliance maxillary molar distalization: A literature review, Eur. J. Orthod. 30:558-571, 2008.
- 3. Kinzinger, G.S.; Wehrbein, H.; and Diedrich, P.R.: Molar distalization with a modified Pendulum appliance: In vitro analysis of the force systems and in vivo study in children and adolescents, Angle Orthod. 75:558-567, 2005.
- 4. Echarri, P.; Scuzzo, G.; and Cirulli, N.: A modified Pendulum appliance for anterior anchorage control, J. Clin. Orthod. 37:352-359, 2003.
- 5. Scuzzo, G.; Pisani, F.; and Takemoto, K.: Maxillary molar distalization with a modified Pendulum appliance, J. Clin. Orthod. 33:645-650, 1999.
- 6. Scuzzo, G.; Takemoto, K.; Pisani, F.; and Della Vecchia, S.: The modified Pendulum appliance with removable arms, J. Clin. Orthod. 34:244-246, 2000.
- 7. Kärcher, H.; Byloff, F.K.; and Clar, E.: The Graz implant supported pendulum, a technical note, J. Craniomaxillofac. Surg. 30:87-90, 2002.
- 8. Escobar, S.A.; Tellez, P.A.; Moncada, C.A.; Villegas, C.A.; Latorre, C.M.; and Oberti, G.: Distalization of maxillary molars with the bone supported pendulum: A clinical study, Am. J. Orthod. 131:545-549, 2007.
- 9. Polat-Ozsoy, O.; Kircelli, B.H.; Arman-Ozçirpici, A.; Pektas, Z.O.; and Uçkan, S.: Pendulum appliances with 2 anchorage designs: Conventional anchorage vs bone anchorage, Am. J. Orthod. 133:339.e9-e339.e17, 2008.
- 10. Wilmes, B.; Katyal, V.; and Drescher, D.: Mini-implant-borne Pendulum B appliance for maxillary molar distalisation: Design and clinical procedure, Austral. Orthod. J. 30:230-239, 2014.
- 11. Grec, R.H.; Janson, G.; Branco, N.C.; Moura-Grec, P.G.; Patel, M.P.; and Castanha Henriques, J.F.: Intraoral distalizer effects with conventional and skeletal anchorage: A meta-analysis, Am. J. Orthod. 143:602-615, 2013.
- 12. Al-Thomali, Y.; Basha, S.; and Mohamed, R.N.: Pendulum and modified pendulum appliances for maxillary molar distalization in Class II malocclusion: A systematic review, Acta Odontol. Scand. 75:394-401, 2017.
- 13. Nappée-Mievilly, M.; Nappée, F.J.; Kerbrat, J.B.; and Goudot, P.: The Pendulis appliance: A palatal miniscrew supported molar distalization device [in French], Orthod. Fr. 85:265-273, 2014.
- 14. Nissen, S.: Commentary: The Pendulum appliance for Class II non-compliance therapy, J. Clin. Orthod. 51:564-567, 2017.
- 15. Wilmes, B.; Ludwig, B.; Vasudavan, S.; Nienkemper, M.; and Drescher, D.: The T-zone: Median vs. paramedian insertion of palatal mini-implants, J. Clin. Orthod. 50:543-551, 2016.
- 16. Ludwig, B.; Glasl, B.; Bowman, S.J.; Wilmes, B.; Kinzinger, G.S.; and Lisson, J.A.: Anatomical guidelines for miniscrew insertion: Palatal sites, J. Clin. Orthod. 45:433-441, 2011.
- 17. Papadopoulos, M.; Melkos, A.; and Athanasiou, A.: Noncompliance maxillary molar distalization with the First Class Appliance: A randomized controlled trial, Am. J. Orthod. 137:586.e1-586.e13, 2010.

- 

DR. NAPPÉE

- 

DR. NAPPÉE-MIÉVILLY

DR. HILGERS

Drs. Nappée and Nappée-Miévilly are in the private practice of orthodontics at 7, rue des Brumes Lactées, 95800 Cergy, France. Dr. Nappée is also a Visiting Professor, Department of Orthodontics, Faculty of Dental Surgery, Lille University, Place de Verdun, Lille, France. Dr. Hilgers is an Associate Professor, Department of Orthodontics, School of Dentistry, Loma Linda University, Loma Linda, CA. E-mail Dr. Nappée at dr.nappee@gmail.com.


Cloud Subscription
SILVER
GOLD
PLATINUM
Choose a monthly package plan that's right for you.
Access Dolphin Imaging and Management software in the cloud with Dolphin Cloud Subscription. ONE SIMPLE MONTHLY PAYMENT PLAN covers data back-up, software updates, unlimited technical support, disaster recovery, and secure hosting in a certified facility. Cloud Subscription is offered in a variety of packages to accommodate the different needs and size of a practice, with plans starting at $180 per month. We take care of your software so you can take care of your patients. Visit www.dolphinimaging.com/cloud.
AAOE
CORPORATE PARTNER
Dolphin
Imaging & Management Solutions
a Patterson Technology
© 2019 Patterson Dental Supply, Inc. All rights reserved.